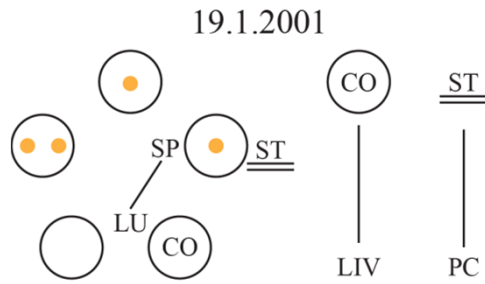


*Phase of Wood*  
*Case History*

**Skin Conditions**

Seborrhea

Adi



Missing Organs: KID, BL, HT, TH

Adi (7 1/2) ♀

7.7.2008

Sister: Shir - 6

**CC:** Seborrhea in the front line of the hair. Starts 2 months ago.

3 months ago the mother had abortion.

They did not changed the shampoo.

The mother suffer from psoriasis in the last 7 years.

**Pregnancy:** ✓.

**Birth:** ✓.

**Appetite:** ✓.

**Stools:** Some times hard, regular. Less at home, prefer to go to the toilet at school.

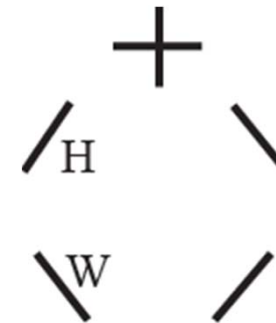
**Night sweats:** ✓.

**Sleeping:** Rapid movements but sleep well. Grinding teeth.

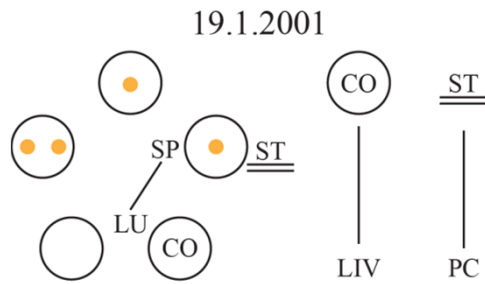
**Mood:** Anger is typical.

2 years ago she was afraid from water, few months ago fright from darkness.

**Phlegm:** ✓.



**T: CO-11**



Missing Organs: KID, BL, HT, TH

Adi (7 1/2) ♀

7 Weeks later

W	T
21.3	CO-11

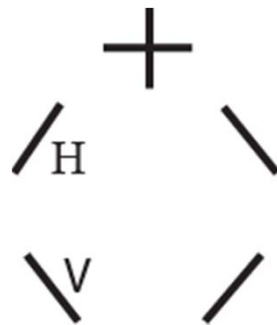
14.7.2008

**Seborrhea:** Few days after the treatment a dandruff appears in the occiput – get worse in expose to the sun.

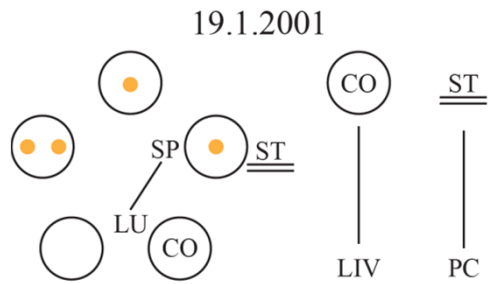
**Sleeping:** At the night after the treatment she was very unquiet while sleeping.

**Teeth grinding:** Unknown. It is possible to hear it only if you sleep beside her. Typical in strong sleep.

**Anger:** She become calm.



**T: LIV-2°**



Missing Organs: KID, BL, HT, TH

Adi (7 1/2) ♀

15 Weeks later

28.7.2008

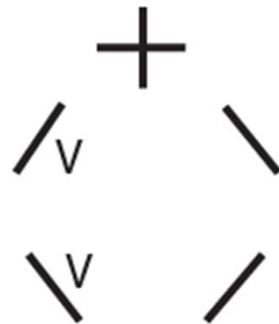
W	T
21.3	CO-11
14.7	LIV-2°

**Seborrhea:** A big improvement.

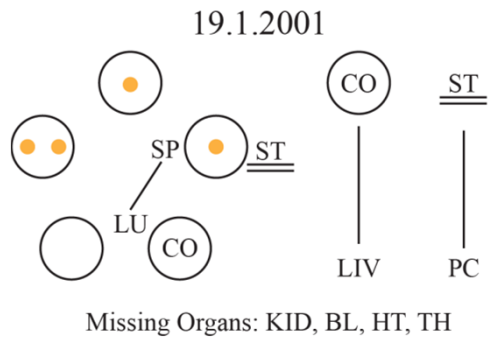
No reaction to the treatment.

**Anger:** Mother is more angry.....

**Sleeping:** ✓.



**T: LU-5**



Adi (7 1/2) ♀

15 Weeks later

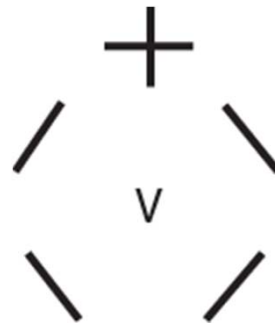6.8.2008

W	T
21.3	CO-11
14.7	LIV-2°
28.7	LU-5

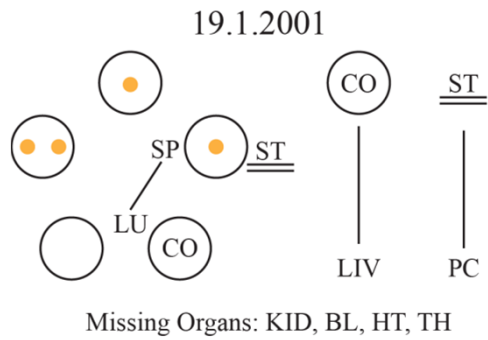
**Seborrhea:** Another improvement.

**Anger:** There is calmness.

**Teeth grinding:** Unknown.



**T: KID-3**



Adi (7 1/2) ♀

11 Days later

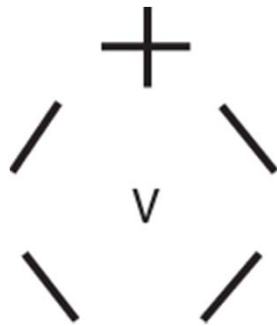
25.8.2008

W	T
21.3	CO-11
14.7	LIV-2°
28.7	LU-5
6.8	KID-3

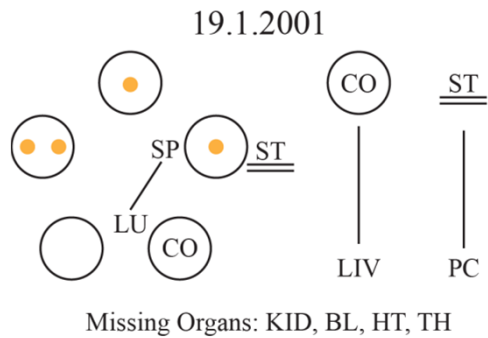
**Seborrhea:** Another improvement, only redness, the occiput is clean.

**Anger:** Reasonable.

**Teeth grinding:** Little, from time to time.



**T: PC-6**



Adi (7 1/2) ♀

3 Weeks later

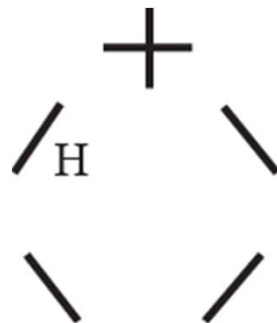
15.9.2008

W	T
21.3	CO-11
14.7	LIV-2°
28.7	LU-5
6.8	KID-3
25.8	PC-6

There is some roughness in the forehead and the occiput, they notice day before yesterday.

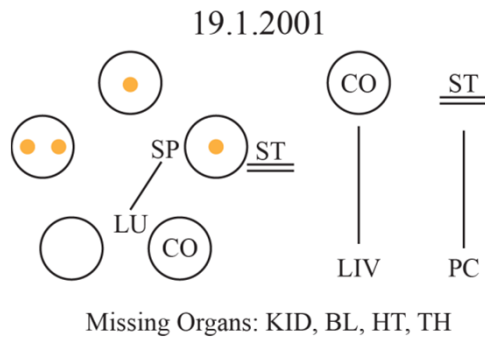
**Teeth grinding:** The mother thinks it stopped.

**Anger:** Not much.



**T: LIV-2°**

*To look for cold*



Adi (7 1/2) ♀

3 Weeks later

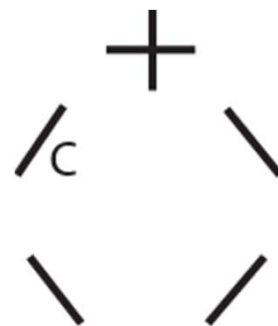
6.10.2008

W	T
21.3	CO-11
14.7	LIV-2°
28.7	LU-5
6.8	KID-3
25.8	PC-6
15.9	LIV-2°

The seborrhea came back

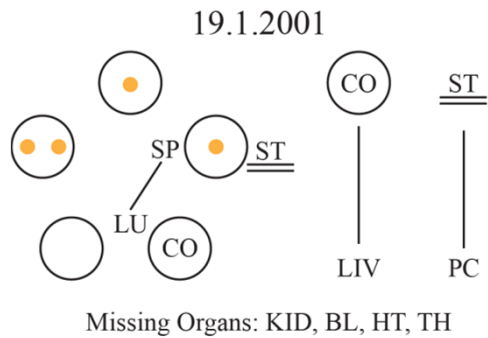
**Anger:** As usual, from time to time, relatively to herself she is less angry.

**Teeth grinding:** Seems that it is vanished.



**T: LIV-8°**





Adi (7 1/2) ♀

2 Weeks later

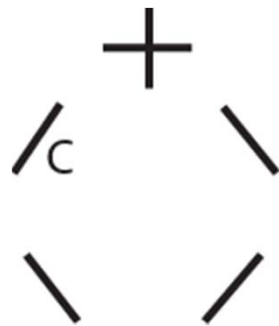
19.10.2008

W	T
21.3	CO-11
14.7	LIV-2°
28.7	LU-5
6.8	KID-3
25.8	PC-6
25.8	LIV-2°
6.10	LIV-8°

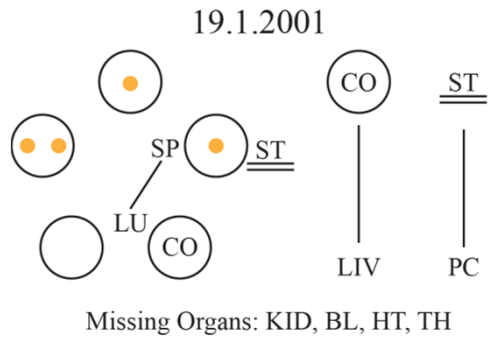
**Seborrhea:** Totally disappear, or at list can't be seen. But the head started to itch.

**Sleeping:** Sleeps strong, not moving.

**Teeth grinding:** Rarely, early in the morning



**T: PC-6**



Adi (7 1/2) ♀

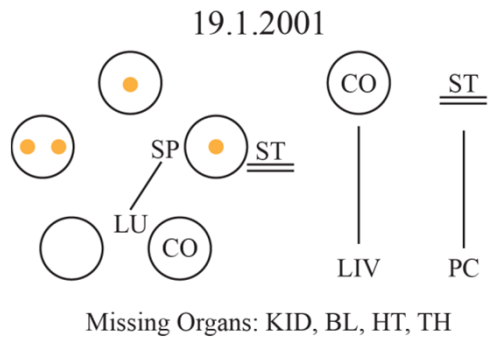
6 Weeks later

1.12.2008

W	T
21.3	CO-11
14.7	LIV-2°
28.7	LU-5
6.8	KID-3
25.8	PC-6
25.8	LIV-2°
6.10	LIV-8°
19.10	PC-6

Seborrhea: Very low level.

*No treatment in this meeting.*



Adi (7 1/2) ♀

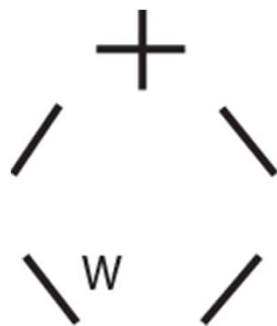6 Weeks later

16.2.2009

W	T
21.3	CO-11
14.7	LIV-2°
28.7	LU-5
6.8	KID-3
25.8	PC-6
25.8	LIV-2°
6.10	LIV-8°
19.10	PC-6
1.12	----

2 weeks ago a dandruff started in the occiput.

**Anger:** Always, small sessions and than she relaxes.



**T: GV-16(G)**

Last treatment