

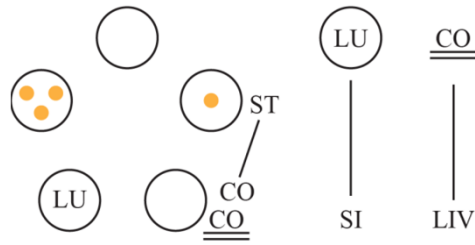
Phase of Wood
Case History

Skin Conditions

Atopic Dermatitis

Ronald

23.7.2011



Missing Organs: GB, HT, TH

Ronald (2) ♂

28.2.2013

Sisters and brothers:
Brother – 6, Sister - 3

CC: Atopic Dermatitis In the last winter the skin was dry. In the summer he was OK.

A month ago gradually the skin become worse.

In the last month he did not slept even one night normally.

He was vaccinated just before.

Blockage in tear duct. Practicing massage. 2 months of acupuncture did not helped. They went to operation but he had rhinitis. Now with the massage it is a bit better.

His sister suffering from a dry skin – homeopathy treatment was helpful.

No history of this problem in the family.

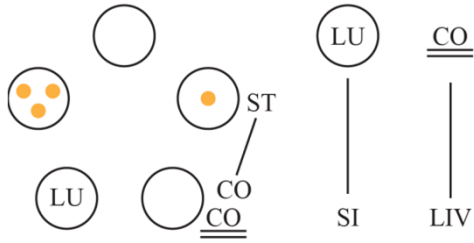
Pregnancy: ✓.

Birth: ✓.

Appetite: ✓.

Teething: Accompanied with fever.

23.7.2011



Missing Organs: GB, HT, TH

Ronald (2) ♂

Sisters and brothers:
Brother – 6, Sister - 3

28.2.2013

AB: ✓.

Stools: ✓.

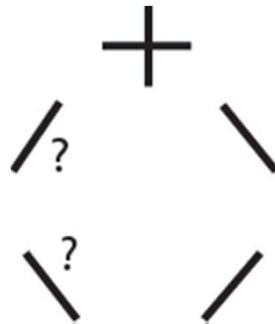
Vaccines: ✓.

Mood: ✓.

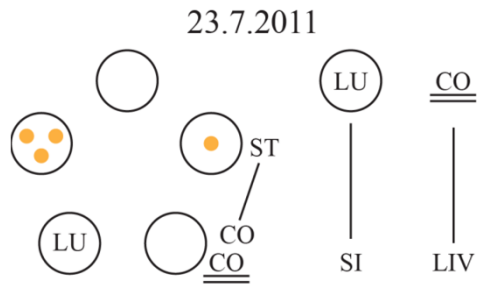
Sleeping: ✓.

Phlegm: Typical in the winter.

Rhinitis: Yellow.



T: CO-11



Missing Organs: GB, HT, TH

Ronald (2) ♂

4.3.2013

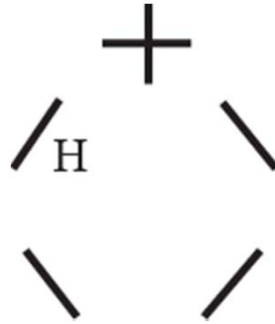
1 week later

W	T
28.2	CO-11

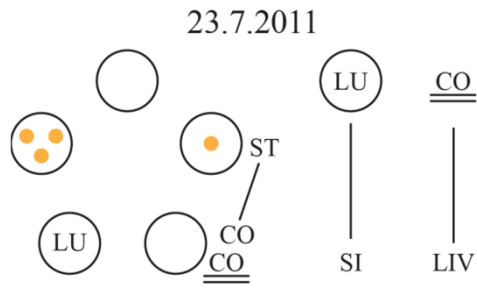
Skin: Improvement.

Tear duct: Improvement.

Sleep: Without change.



T: LIV-2° ↔ B



Missing Organs: GB, HT, TH

Ronald (2) ♂

13.3.2013

1 week later

W	T
28.2	CO-11↔B
4.3	LIV-2°↔B

After the treatment he slept the all night – first time after one month.

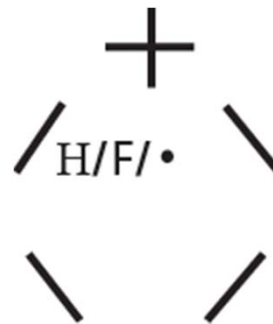A.D: After the treatment the skin condition become worse, he scratch also in day time.
The cheeks are better.

Tear duct: Some improvement, but still discharge from time to time.

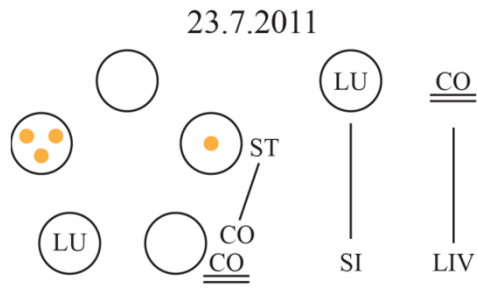
Rhinitis: Still – clear, yellow.

A lesion appeared behind the ear.

He stopped teething.



T: SP-4, LIV-1°



Missing Organs: GB, HT, TH

Ronald (2) ♂

18.3.2013

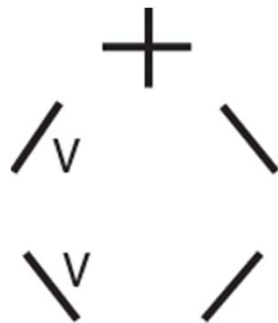
1 week later

W	T
28.2	CO-11↔B
4.3	LIV-2°↔B
13.3	SP-4, LIV-1°↔B

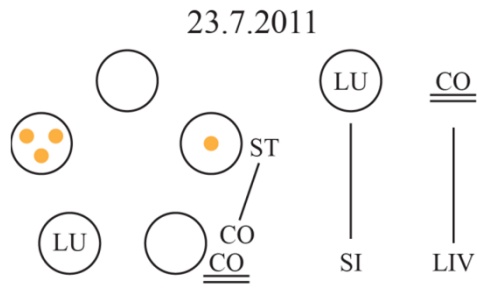
After the treatment he felt good for 2-3 days. In the last 2 days he feels less good.

They will stop cow's milk product.

Before he felt bad he ate cheese.



T: LU-5



Missing Organs: GB, HT, TH

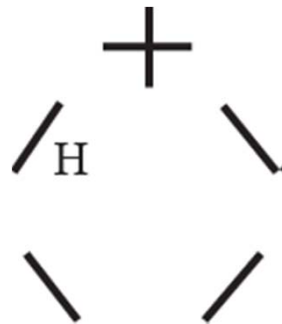
Ronald (2) ♂

25.3.2013

5 days later

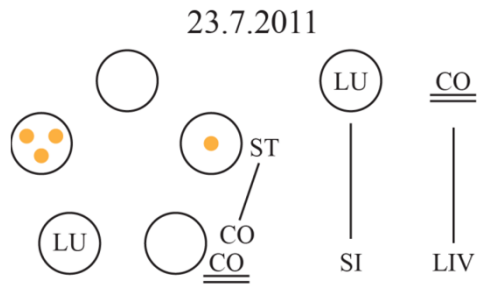
W	T
28.2	CO-11↔B
4.3	LIV-2°↔B
13.3	SP-4, LIV-1°↔B
18.3	LU-5

A.D: The face looks much better, the back is worse.
Scratching in the nights but not in the days.



T: LIV-2°

Tears duct



Missing Organs: GB, HT, TH

Ronald (2) ♂

15.4.2013

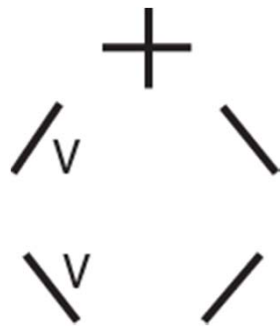
3 weeks later

W	T
28.2	CO-11↔B
4.3	LIV-2°↔B
13.3	SP-4, LIV-1°↔B
18.3	LU-5
25.3	LIV-2°↔B

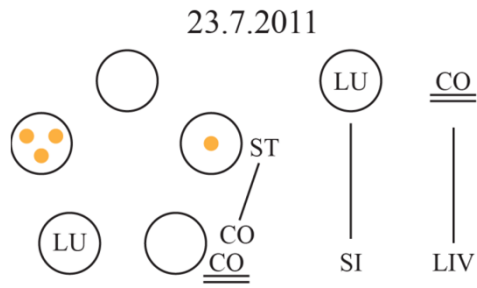
I was in Europe – He was treated by Asaf.

After 2 weeks with out cow's milk products, the conclusion is that there is no connection to his problem.

A big improvement in the face and the body.



T: BL-67''



Missing Organs: GB, HT, TH

Ronald (2) ♂

25.4.2013

3 weeks later

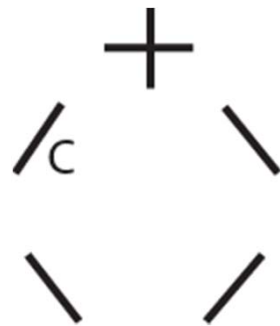
W	T
28.2	CO-11↔B
4.3	LIV-2°↔B
13.3	SP-4, LIV-1°↔B
18.3	LU-5
25.3	LIV-2°↔B
15.4	BL-67''

During the days he feels good.

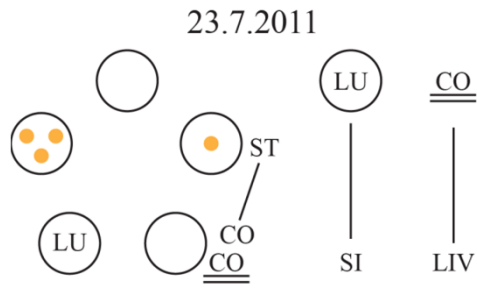
Difficulty to fall asleep.

A.D: The level of the skin problem is much much better, but he still scratching.

Tears duct: It is worse. As always the condition of the eye is changing.



T: LIV-8°



Missing Organs: GB, HT, TH

Ronald (2) ♂

6.5.2013

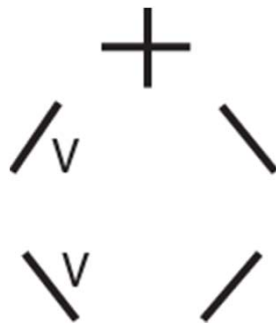
10 days later

W	T
28.2	CO-11↔B
4.3	LIV-2°↔B
13.3	SP-4, LIV-1°↔B
18.3	LU-5
25.3	LIV-2°↔B
15.4	BL-67''
25.4	LIV-8°↔B

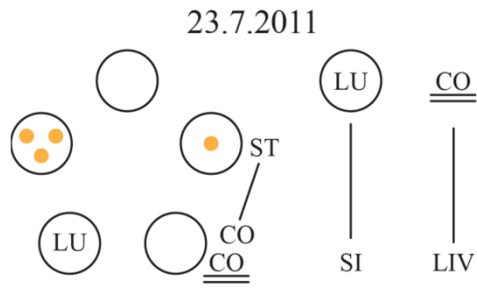
Tears duct: Open, lately there nothing in the eye.

Skin: Improvement. Still scratching.

Sleep: Good.



T: SI-7↔S



Missing Organs: GB, HT, TH

Ronald (2) ♂

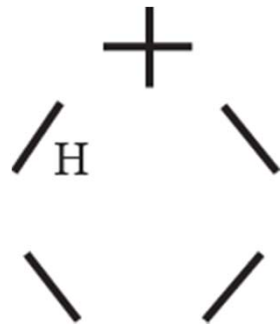
12.8.2013

13 weeks later

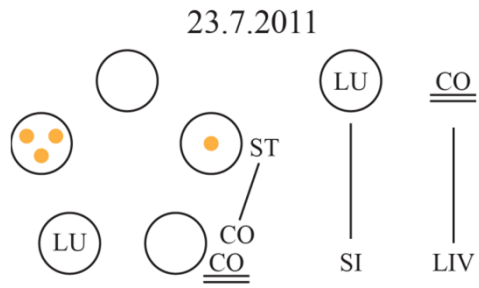
W	T
28.2	CO-11↔B
4.3	LIV-2°↔B
13.3	SP-4, LIV-1°↔B
18.3	LU-5
25.3	LIV-2°↔B
15.4	BL-67''
25.4	LIV-8°↔B
6.5	S-7↔S

A week ago hid skin started to scratch again – not clear what is the reason.

I the last week he is not sleeping.



T: LIV-2°



Missing Organs: GB, HT, TH

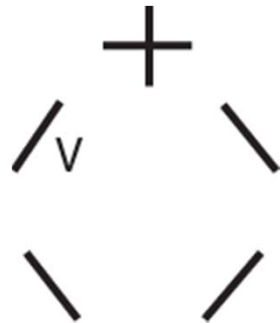
Ronald (2) ♂

15.8.2013

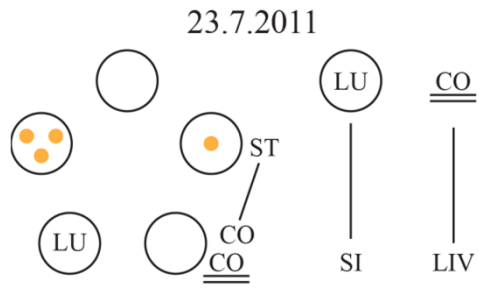
3 days later

W	T
28.2	CO-11↔B
4.3	LIV-2°↔B
13.3	SP-4, LIV-1°↔B
18.3	LU-5
25.3	LIV-2°↔B
15.4	BL-67''
25.4	LIV-8°↔B
6.5	S-7↔S
12.8	LIV-2°↔B

No improvement yet.



T: LU-5



Missing Organs: GB, HT, TH

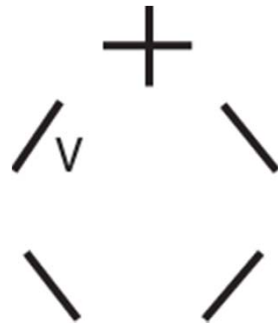
Ronald (2) ♂

2.9.2013

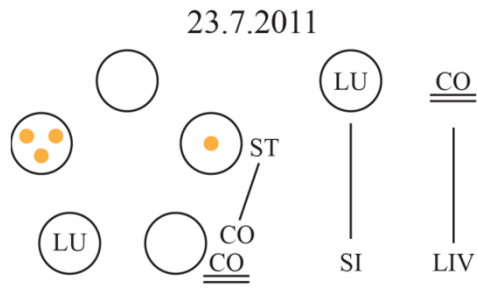
3 days later

W	T
28.2	CO-11↔B
4.3	LIV-2°↔B
13.3	SP-4, LIV-1°↔B
18.3	LU-5
25.3	LIV-2°↔B
15.4	BL-67''
25.4	LIV-8°↔B
6.5	S-7↔S
12.8	LIV-2°↔B
15.8	LU-5

Still scratching.



T: KID-10



Missing Organs: GB, HT, TH

Ronald (2) ♂

1 week later

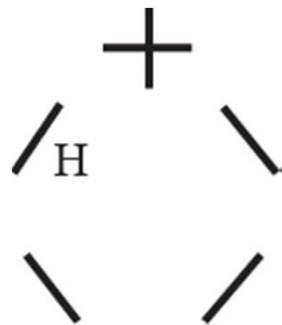
9.9.2013

W	T
28.2	CO-11↔B
4.3	LIV-2°↔B
13.3	SP-4, LIV-1°↔B
18.3	LU-5
25.3	LIV-2°↔B
15.4	BL-67''
25.4	LIV-8°↔B
6.5	S-7↔S
12.8	LIV-2°↔B
15.8	LU-5
2.9	KID-10

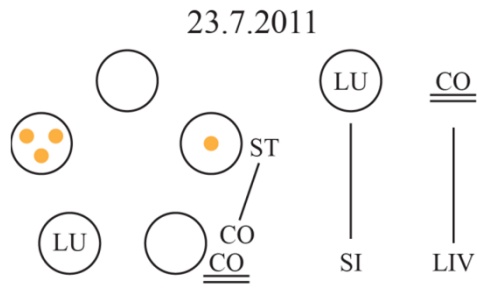
His face looks better, but he is not sleeping, wakes up and scratch every half an hour. The hands and legs looks very bad, wakes up in the morning full with blood.

during the day he scratch just a little bit.

He got a polio vaccine 2 weeks ago.



T: LIV-2°



Missing Organs: GB, HT, TH

Ronald (2) ♂

30.9.2013

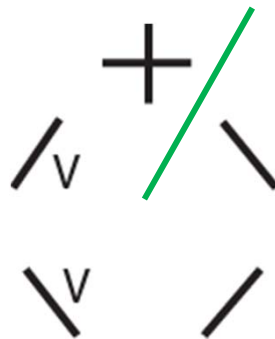
1 week later

W	T
28.2	CO-11↔B
4.3	LIV-2°↔B
13.3	SP-4, LIV-1°↔B
18.3	LU-5
25.3	LIV-2°↔B
15.4	BL-67''
25.4	LIV-8°↔B
6.5	S-7↔S
12.8	LIV-2°↔B
15.8	LU-5
2.9	KID-10
9.9	LIV-2°↔B

Generally he is improving all the time, except from the last night.

The father asking to disperse heat.

Maybe a bit +



T: CO-11, ST-44

Last treatment